

ACQUIRED CENTRAL DYSCHROMATOPSIA: ANALYSIS OF A CASE WITH PRESERVATION OF COLOR DISCRIMINATION

JONATHAN D. VICTOR,^{1,2} KENNETH MAIESE,¹ ROBERT SHAPLEY,^{2*} JOHN SIDTIS¹
and MICHAEL S. GAZZANIGA¹

¹Department of Neurology, The New York Hospital—Cornell Medical Center, 525 E. 68th Street,
New York City, NY 10021 and ²Laboratory of Biophysics, The Rockefeller University,
1230 York Avenue, New York City, NY 10021, U.S.A.

(Received 4 February 1988; in revised form 20 September 1988)

Summary—1. It is well-known that a focal cerebral lesion may, on rare occasions, cause a selective disturbance of color vision (Critchley, 1965; Meadows, 1974). However, the roles of striate and extrastriate lesions in central abnormalities of color vision may be difficult to separate.

2. A patient is described who had a right homonymous hemianopsia and marked dyschromatopsia in the otherwise-spared left visual field. The patient could not identify saturated colors reliably and had grossly-abnormal performance on the Farnsworth–Munsell 100-Hue test. However, chromatic contrast-sensitivity was normal and VEPs to isoluminant gratings were present. A magnetic resonance imaging (MRI) study demonstrated extensive infarction of the left occipital lobe and a small infarction of the ventromedial portion of the right occipital lobe.

3. This case demonstrates that even with marked dyschromatopsia, sensitivity to color differences may be preserved. On the basis of this case and a review of previous cases of central disturbances of color vision, it is proposed that preservation of chromatic contrast-sensitivity reflects residual function of primary visual cortex.

Key words—Achromatopsia; contrast sensitivity; dyschromatopsia; Farnsworth–Munsell test; human; magnetic resonance imaging; visual cortex; visual evoked potentials.

INTRODUCTION

Central achromatopsia is a selective or dissociated loss of color vision due to cerebral dysfunction; central dyschromatopsia is the analogous partial loss or distortion of color vision. For many years, the very existence of these phenomena was doubted (Holmes, 1918). However, after a number of careful descriptions (Critchley, 1965; Meadows, 1974; Green and Lessell, 1977; Damasio *et al.*, 1980), the entity has become regarded as distinct, although somewhat unusual. Damasio *et al.* (1980) have provided evidence that this visual disturbance correlates with lesions in the ventromedial portion of the occipital lobe contralateral to the involved field. Several authors have proposed that this syndrome is the result of damage to a cortical region specialized for color processing (Green and Lessell, 1977; Pearlman *et al.*, 1978;

Damasio *et al.*, 1980; Heywood *et al.*, 1987), and have proposed that this specialized region corresponds to area V4 of the primate, as characterized by Zeki (1973, 1977).

One problem in defining the psychophysical and behavioral manifestations of a central lesion affecting color vision is the need to separate processing at post-striate levels from processing at earlier stages. Accumulated electrophysiological evidence, while not questioning the specialization of V4 for color processing, demonstrates that exquisite sensitivity of chromatic differences are present in the retinal output, and also in the activity of individual neurons of striate cortex (Gouras, 1972; Dow and Gouras, 1973; DeMonasterio and Schein, 1982).

Earlier reports (e.g. Damasio *et al.*, 1980) of central achromatopsia characterized the patients' perception of the visual world as consisting of various shades of gray. Although CT evidence in these patients suggested sparing of striate cortex (area 17), the reported electrophysiological evidence of absent or grossly-

*Present address: Department of Psychology, New York University, 6 Washington Place, New York City, NY 10003, U.S.A.

disturbed chromatic VEP's implies *involvement* of striate cortex (Previc, 1986). Thus, it is unclear whether the complete absence of color sensitivity reported in these patients is the result of a purely extrastriate lesion, or rather, of a lesion involving both striate and extrastriate visual areas.

The patient described here has selective, partial, loss of color vision in his nonhemianopic field, and shares many neuropsychological similarities with previously-described cases of central achromatopsia and dyschromatopsia. The unusual finding in this patient is that some aspects of color vision are preserved (discrimination of hues and use of chromatic cues to separate figure from background), while others (grouping of items of similar color, naming of colors of unfamiliar objects, and arrangement of samples of colors in sequence) are grossly disturbed.

Magnetic resonance imaging (MRI) demonstrated a lesion which included the ventromedial portion of the occipital lobe but spared the occipital pole (striate region). Evoked potentials to isoluminant chromatic stimuli were present. On the basis of this case and other previously-reported cases, it is proposed that the partial preservation of the ability to use color information results from the rudimentary color processing performed in striate cortex, while the aspects of color vision which are disturbed require additional cortical processing.

CASE HISTORY

M.S. is a 55-yr-old right-handed Chinese male stockbroker with noninsulin-dependent diabetes mellitus, hypertension, and no prior neurologic history. 10 days prior to admission, the patient reported a visual disturbance to his relatives and experienced difficulty finding his way through his apartment building. On the day of admission, he was found by his relatives on the floor, unclothed and confused. The patient did not recognize his brother until the brother spoke to him. He was apparently unable to recognize the apartment as his own, and said, "Thank heaven you have rescued me. I have been confined to this strange apartment but have fortunately located a refrigerator." He then stated that he had been unable to operate the television set or telephone, although he had been able to ration himself food over the prior 10 days.

On admission, he was alert and oriented to place but not year. The general medical exam

was normal except for newly-noted atrial fibrillation. Routine neurological examination revealed a complete macula-splitting right homonymous hemianopsia, and normal motor function except for a left extensor plantar response. Language function was tested in English only; the patient had lived in the United States since age five, spoke without an accent, and stated that he thought in English. Spontaneous speech was fluent and grammatical. There was delay in naming "watch face" and "belt buckle", and inability to identify colors of unfamiliar objects (e.g. book jackets). Words presented in the left visual field could not be read reliably until the letters were said aloud. Simple calculations were performed correctly. He was able to recall two of five objects at 1 min, and none at 5 min. He had poor recall of the previous week, but could recall stock prices from 3 weeks previous. Simple proverbs were interpreted concretely. There was difficulty imitating the examiner's finger constructions. The right side of space was neglected in all modalities.

A computerized tomographic (CT) scan demonstrated bilateral occipital lesions with gyral enhancement suggestive of recent infarction. Magnetic resonance imaging (MRI) (Fig. 1) demonstrated extensive occipital infarction on the left with areas of hemorrhagic change, and a smaller right occipital infarction which spared the occipital pole and involved primarily the ventromedial portion of the occipital lobe. The MRI also suggested infarction of the splenium of the corpus callosum. Lumbar puncture was normal except for an elevated glucose of 158 mg/dl and protein of 82 mg/dl. Serum glucose was 306 mg/dl; other routine chemistries and hematologic studies were normal. He was treated with heparin anticoagulation for cerebral emboli of presumed cardiac source (Pessin *et al.*, 1987). Digoxin, quinidine, and d.c. cardioversion were administered to control the ventricular response rate; digoxin levels remained in the low therapeutic range for the duration of his course.

Four days after admission, examination revealed fluent and grammatical speech, with intact ability to repeat and name objects. The inability to read without first saying the letters aloud persisted; writing was relatively unimpaired. There was no left-right confusion, no difficulty with identification of fingers or other body parts, and no difficulty performing complex motor sequences. Three-digit mental subtractions were performed correctly. Two of

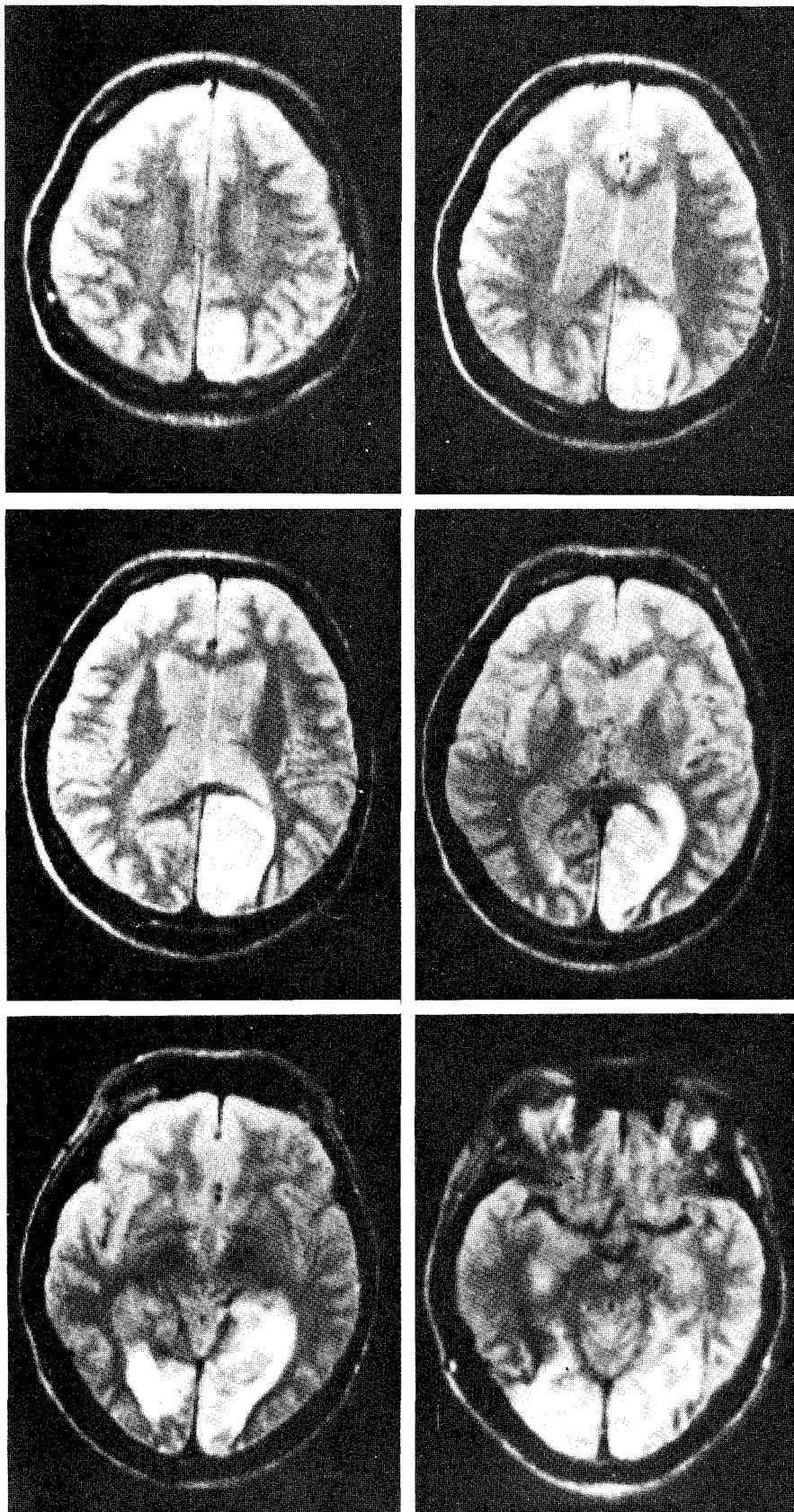


Fig. 1. An MRI obtained on the second hospital day, approx. 12 days following the onset of neurological dysfunction. The *left* hemisphere, on the *right* of each image, demonstrates an extensive occipital lesion in all sections. The *right* hemisphere demonstrates a smaller, deep lesion most prominent in the first section of the bottom row. MRI parameters: TR = 2150 ms; TE = 60 ms; slice thickness = 0.75 cm.

three objects, and the initial letter of the third object, were correctly recalled after 3 min. The patient correctly identified the four house-officers he had previously seen out of a group of 10 house-officers. Optokinetic responses were normal. There was no difficulty with dressing. He could not find his way back to his room without assistance, and he could not describe his apartment. Finger constructions were imitated rapidly and accurately. Cortical sensory function, as tested by the ability to recognize digits drawn on the palm and small objects placed in the palm was intact, and the patient could transfer the pose of one hand to the other without visual cues.

Static perimetry demonstrated a complete macula-splitting right homonymous hemianopia (Fig. 2). The patient correctly interpreted eight of nine Ishihara pseudo-isochromatic plates, although in several cases, he was unable to name the numeral until he traced its outline with his right thumb. Visual acuity was 20/70 in each eye without correction; subsequent to discharge, vision was correctable to 20/20 (Snellen) with lenses. Slit-lamp and dilated funduscopic examinations were normal.

The patient had marked difficulty identifying the color of unfamiliar objects. Red objects were usually identified as red, but yellows, greens, and blues were confused. He was asked to sort by color an assortment of 16 markers of various hues and brightnesses. He readily segregated a pile consisting of three red markers and one pink marker, and identified the pile as "red". With more difficulty he selected out the three yellow ones, but identified the color as "cream or brown." Greens and blues could not be sorted. When asked to select the single green marker from a pile which included brighter and darker blue markers, he stated that "green is a lighter color" and then selected the lightest marker (which was blue). Similarly, he selected the darkest marker when asked to select the single blue marker from a pile of brighter and darker green ones.

The difficulty with color identification did not appear to be related to language dysfunction. The patient could correctly answer questions like "What color is the sky", and could correctly answer "yellow" when shown a line-drawing of a banana and asked what color the object should be.

Scotopic and photopic flash electroretinography was normal in implicit time and amplitude. 30 Hz flicker ERG response was also

normal. These studies indicated normal rod and cone function.

EXPERIMENTAL METHODS AND RESULTS

General neuropsychologic evaluation

A neuropsychologic battery was administered on the sixth hospital day. On general mental status testing, the patient was fully oriented. Recall of personal and current information was intact, as was mental control as assessed by timed serial addition, backward counting, and alphabet recitation. Forward and backward digit span and immediate recall of a standard story were normal; recall after 20 min was poor (0/24 details correct; Wechsler, 1945). On a three-trial word-pair associative learning test (Wechsler, 1945), the patient scored 5/9 on easy associations but failed to learn any of the difficult associations. Visual reproduction tests of the Wechsler Memory Scale could not be performed by the patient.

The patient's spontaneous speech was fluent and grammatical with no word- or phonemic-substitution errors. On the Boston Naming Test (Kaplan *et al.*, 1983), naming was slow and labored, and only 8 of the first 20 drawings were correctly named without cueing. Seven of the remaining 12 drawings were named with a semantic cue, and phonetic cue failed to assist naming in the remaining five test items. Of note, the patient described features of the drawings in isolation before naming the object (i.e. that the teeth of a saw appeared to be a key) on nine of the trials. He also commented that naming the line drawings was more difficult than naming pictures or real objects.

In a dichotic listening test (Springer and Gazzaniga, 1975; Sidtis *et al.*, 1981a), the patient correctly reported 87.5% of the right-ear syllables, but was unable to report any of the left-ear syllables. Formal tests of somatosensory function revealed essentially normal within-hand point localization and between-hand transfer. Errors in the between-hand condition occurred only when points stimulated on the left hand were to be reproduced on the right hand, and two-thirds of the errors were referable to the fifth digit.

The neuropsychological battery demonstrated a mild to moderate learning deficit, moderate difficulty in naming, and abnormal auditory processing of syllables presented to the left ear. The auditory abnormalities suggest a disruption of interhemispheric communication,

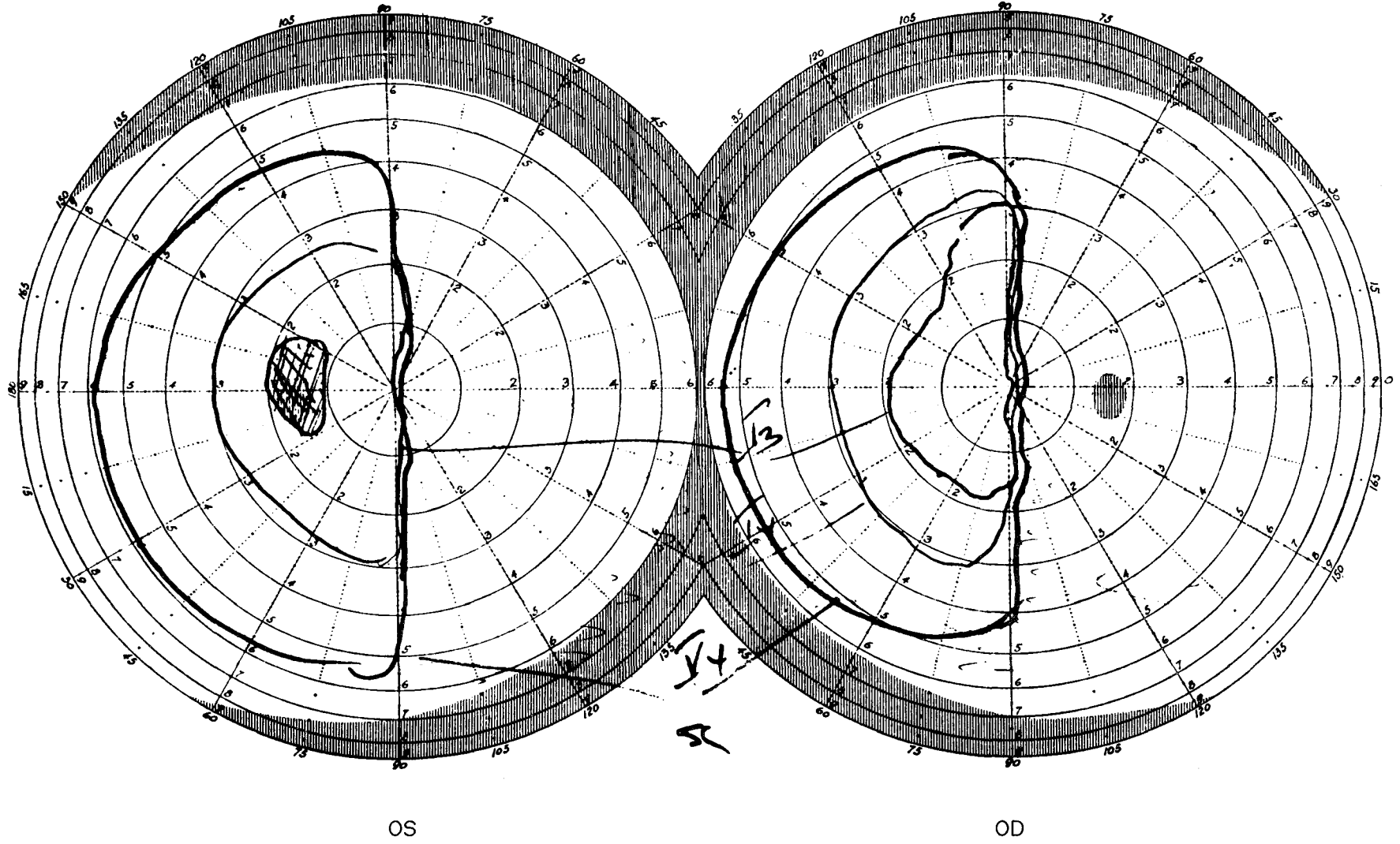


Fig. 2. Static perimetry obtained with the Goldmann apparatus approx. 2 weeks following the onset of neurologic dysfunction. The visual field loss splits the center of gaze in both eyes.

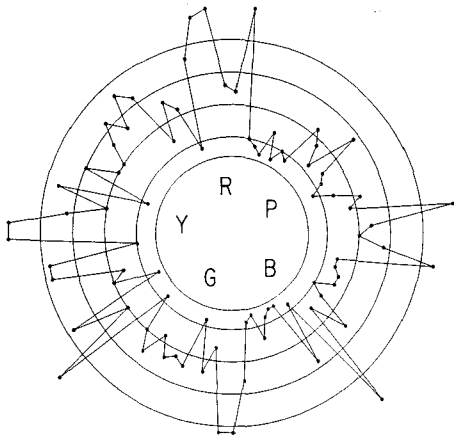


Fig. 3. The patient's performance on the Farnsworth-Munsell test of color discrimination. The position around the circle indicates the color of the test cap (R: red; P: purple; B: blue; G: green; Y: yellow); the distance of each point from the center indicates the degree of mismatch the corresponding color sample. Data from normal subjects would lie near the inner circle.

which may be the result of a lesion of the corpus callosum or its projection fields (Damasio and Damasio, 1979; Sidtis *et al.*, 1981a, b).

Special tests of visual function

Color vision. The Farnsworth-Munsell 100-Hue Test was administered beginning on the fourth hospital day. In this test, the subject is asked to sort four trays, each consisting of 21 or 22 colored caps, according to color. The patient required 30 min to an hour to sort each box, and for this reason, each box was given in a separate session over the following 4 days. His performance on this test (Fig. 3) was grossly abnormal. The pattern of errors, which included all regions of the color circle, was typical of that reported in previous cases of central achromatopsia (Meadows, 1974; Pearlman *et al.*, 1978; Heywood *et al.*, 1987). Overall performance on this test may be calculated by a "total error score" (Farnsworth, 1957). The patient's total error score was 850; typical performance of a normal subject results in an error score of 120 or less. However, the total error score of 850 represents performance which is significantly better than random performance, which would result in an error score of approx. 1200; the probability that a total error score of 850 or less is due to chance alone is less than 0.001 (Victor, 1988). The pattern of errors in Fig. 3 appears to show somewhat more accurate performance in the red-purple region of color

space, as suggested by the informal observations above. However, the apparent asymmetry of performance does not reach statistical significance ($P = 0.1$ by the method of Victor, 1988).

Although the patient indicated that he clearly understood the Farnsworth-Munsell task, we were concerned that his performance may have been limited by cognitive or motor factors not specific to color perception and discrimination. For this reason, we administered a simplified version of the Farnsworth-Munsell test. The patient was presented with three caps and asked to select the pair which matched most closely. In this manner of administration, correct responses would be given by chance alone one-third of the time. Testing on the 14th hospital day suggested that the patient was able to accomplish the task correctly only when the caps were widely separated in color space (Table 1). More extensive testing on the 47th day following admission demonstrated the same pattern more clearly. This demonstrates that the patient retained the ability to make crude color judgements, and that his poor performance on the Farnsworth-Munsell test was not simply due to cognitive or motoric difficulties.

We next explored the possibility that the preservation of the ability to identify the digits on the Ishihara plates represented preservation of the ability to discriminate colors, but perhaps not identify them. For this purpose, we used tests of preattentive vision, modeled after those of Treisman (1982). These tests were administered on the 15th hospital day.

To test the ability to distinguish colors, cards were constructed which contained 39 patches of one color and one patch of the opponent color, randomly-positioned within an 8 by 5 array. Three cards contained 39 red rectangles and one

Table 1. Performance on a simplified Farnsworth-Munsell task. The patient was presented with three caps from the Farnsworth-Munsell test, and asked to choose which two were the closest match. There were three types of test conditions: two caps diametrically apart, and the third cap 10 positions away from one of the ends (indicated as 10-42), two caps one-quarter of a cycle apart, and the third cap six positions away from one of the ends (indicated as 6-21), and two caps one-eighth of a cycle apart, and the third cap three positions away from one of the ends (indicated as 3-10). Performance is indicated as (number correct/number of trials); chance performance is one-third correct

	Test condition		
	10-42	6-21	3-10
Day 14	3/3	3/5	1/3
Day 47	6/8	12/12	6/12

green rectangle; three contained 39 green rectangles and one red rectangle; the rectangles were randomly horizontal or vertical. Another set of six cards was constructed with blue and yellow rectangles, and a third set was constructed with red and green squares of equal area. Intensities of the rectangles were varied randomly over a factor of two, so that only chromatic cues, and not brightness cues, could be used to identify the uniquely-colored patch. The cards were held at a distance of 30 cm (the rectangles were approx. 0.5 by 1 deg on 1.5 deg centers) within the patient's nonhemianopic field, and all 18 cards were presented twice. The task was to point to the patch with the unique color. For the patient, the average time per card to accomplish this task was 3.5 s. There was no difference between the patient's performance on the red/green and blue/yellow cards, or between the cards with squares and the cards with rectangles. Three normals, tested under the same conditions, required an average time per card of 1.2 s. The patient spontaneously commented that this task was not difficult, and that he saw the unique patch "right away". However, when asked to name the colors, he was uncertain and unreliable: for example, the green patches were called "tan or light green".

We used a similar test of orientation-discrimination (which appeared normal to informal testing) to determine to what extent the increased response latency was specific to the color-discrimination task. This set of cards were constructed with 39 rectangles at one orientation (horizontal or vertical) and one rectangle at the orthogonal orientation, randomly-positioned within the 8×5 array. For the patient, the average time per card to detect the unique rectangle was 4.5 s. There was no difference between performance on cards containing only white rectangles, or containing green/red or blue/yellow mixtures. Three normals, tested in the same fashion, required an average time of 1.6 s.

Thus, although the patient's performance was slower than that of normals, his performance on the color-discrimination task was comparable to (or even better than) his performance on the orientation discrimination task. This is particularly notable in view of the fact that the patient could not reliably identify the colors of the patches.

As a final test, we used a third group of cards which again had 40 rectangles in two opponent colors and two orientations. On these cards, all

rectangles of one color had one orientation, and all *but one* rectangle of the opponent color had the complementary orientation. The same saturated hues were used as in the previous stimuli. The task was to find the unique rectangle; no clues were given as to the color or orientation of the target rectangle. Correct identification of the unique rectangle thus required not only perception of color differences but also association of each color class with its proper orientation. In this "orientation \times color" task, the patient required an average of 107.9 s to complete each of 12 cards; three normal subjects required an average of 6.0 s. The disproportionate difficulty of this task for this patient is notable in that the task is primarily nonverbal, and uses supra-threshold stimuli that the patient was able to identify readily.

Stereoscopic vision. Stereoscopic vision was tested with the random-dot stereograms of Figs 8.1-2A to 8.1-2G of Julesz (1971). Depth information is contained only in binocular correlation between the images. On the 15th hospital day, the patient readily appreciated the binocular percept at a binocular correlation of 60%, and had a weak sense of stereopsis at 50%. This is typical of normal subjects.

Brightness perception. The patient's threshold for brightness discrimination was not tested formally, but he was easily able to sequence patches of gray whose reflectances differed by approx. 7%. This is comparable to the performance of the patient reported by Heywood *et al.* (1987).

At least two processes contribute to supra-threshold processing of brightness. One mechanism, responsible for the extraction of contrast information, is responsible for the tendency of a gray region to appear brighter if it is adjacent to a darker region than if it is adjacent to a brighter region. The second mechanism, assimilation (Helson, 1963), is antagonistic to the local contrast mechanism. Assimilation is responsible for the tendency for an object to be perceived as brighter if it is surrounded by other bright objects. Extraction of contrast is local, and is thought to be retinal (Heinemann 1972); assimilation is a more long-range interaction and thought to be cortical (Shapley and Reid, 1985). The patient readily demonstrated both simultaneous contrast phenomena (as tested by Figs 1 and 2 of Shapley, 1986) and assimilation (as tested by Fig. 9 of Shapley, 1986). These brightness-perception tests were administered on the 15th hospital day.

Table 2. The patient's psychophysical threshold for the detection of luminance and chromatic gratings. Chromatic gratings were isoluminant, as determined by flicker photometry

	0.3 c/deg	2.5 c/deg	10.0 c/deg
Luminance	10%	0.5%	1%
Chromatic	2%	2%	4%

Grating acuity. 42 days after admission, additional tests were performed to assay luminance-sensitive and color-sensitive channels. At this point, the general neurological examination, visual fields, visual acuity, and the difficulty with color identification were unchanged since the fourth hospital day.

For these tests, stimuli were generated on a Tektronix 690SR high-speed, high resolution RGB raster display. The raster display, which subtended a visual angle of 6.4 deg at a viewing distance of 228 cm, had a mean luminance of 30 cd/m², a resolution of 256 × 256 pixels, and a frame rate of 135 Hz. The analog control signals [*X* (horizontal deflection), *Y* (vertical deflection), *R* (red gun), *G* (green gun) and *B* (blue gun)] for the display were generated by specialized hardware (Milkman *et al.*, 1980) interfaced to a DEC 11/23 computer. *R*, *G* and *B* voltages were corrected by digital circuitry to provide for a linear voltage/intensity relationship.

Since it was critical to separate luminance-sensitive from color-sensitive mechanisms, the isoluminant ratio for the red and green guns was determined for the patient by flicker photometry at 20 Hz. The patient reproducibly reported a minimum of perceptible flicker for substitution of a 40% *R* increment with a 16% *G* increment. This ratio, within the range encountered in normal observers [(40% *R*, 12% *G*)–(40% *R*, 20% *G*)], was used for the construction of isoluminant stimuli in later testing.

Detection thresholds for static horizontal sine gratings were determined by an adjustment procedure. Achromatic luminance gratings were initially presented at a contrast of 0.4, where luminance contrast is defined as $(L_{\max} - L_{\min}) / (L_{\max} + L_{\min})$; the experimenter decreased the luminance contrast until the grating pattern became invisible. Isoluminant chromatic (red/green) gratings were initially presented with a *R* contrast of 0.4, and a counterphase *G* contrast of 0.16, where chromatic contrast was the average of the absolute value of the contrast produced in the red cone

array and the green cone array, as calculated from the data of Smith and Pokorny (1975) and Schnapf *et al.* (1987). For the chromatic gratings, the experimenter decreased the chromatic contrast while maintaining a constant *R/G* ratio until the grating pattern became invisible to the subject.

Results for luminance and chromatic contrast are presented in Table 2. The sensitivity to luminance gratings shows the characteristic bandpass dependence on spatial frequency, while the sensitivity to isoluminant chromatic gratings shows no decrement at low spatial frequencies. This pattern, and the absolute thresholds, are similar to those of normal observers under similar conditions (Mullen, 1985). However, although the patient was able to identify the red bars of the grating as "red", he described the other bars as "a color, but not red."

While this testing procedure would not suffice to reveal a fortuitously-placed narrow-band sensitivity loss, it demonstrated that there was normal chromatic and achromatic contrast sensitivity for a range of patterns, and that the inability to identify colors was not due to an inability to perceive chromatic contrast.

Visual evoked potentials. Steady-state evoked potentials were measured in response to contrast-reversing checkerboards, with a check size of 0.4 deg. In all cases, the modulated *R* gun contrast was 0.4; a counterphase *G* gun contrast was varied from episode to episode in the range 0.0 to 0.4. The temporal period of the stimulus was 4.0 Hz (reversal rate of 8/s). The scalp signal, measured at *C_z–O_z* with standard gold cup electrodes, was filtered (0.1 to 300 Hz bandpass) and amplified 10000× prior to digitization at the frame rate of 135 Hz and averaging by the 11/23 computer. Runs were 15 s long.

Evoked-potential records are shown in Fig. 4A. For all amounts of counterphase *G* modulation, a clearly-visible response at the second harmonic of the stimulus frequency (i.e. the reversal rate) was obtained. These responses were quantified by Fourier analysis (Fig. 4B and C). Although there is a diminution of the response size at the isoluminant point, this diminution is at most 40%. Even for pure chromatic modulation (i.e. counterphase *G* contrast of 0.16), a substantial evoked potential, whose phase was identical to the phase of the luminance-modulated stimuli, was obtained.

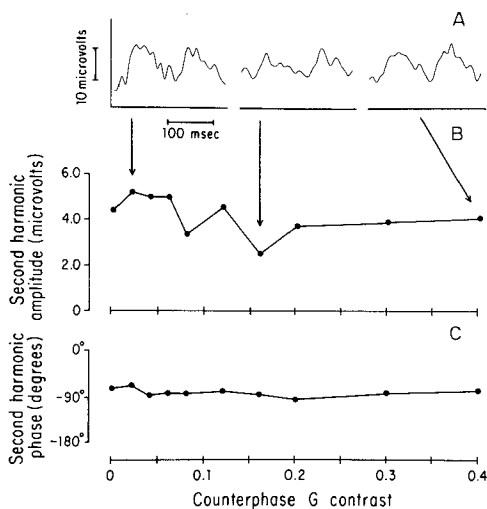


Fig. 4. Steady-state evoked-response testing. *Panel A:* Steady-state responses to 4 Hz modulation of chromatic checkerboards at three R:G contrast ratios. The R gun modulation produced a contrast of 0.4; the counterphase G gun modulation varied from 0.0 to 0.4 across stimulus conditions. A R:G ratio of 2.5:1 was (counterphase G modulation of 0.16) a pure chromatic (isoluminant) stimulus. *Panel B:* Second-harmonic amplitudes extracted from the data of Panel A by Fourier analysis. *Panel C:* Phases of second-harmonic Fourier components. Although there is some diminution of the response near the isoluminant point, easily-identifiable VEP components with similar phases are observed for pure chromatic stimulation.

DISCUSSION

The patient reported here had incomplete loss of color vision in his intact hemifield characterized by inability to name colors, inability to sort colors into categories, and inability to sequence colors in color space (as tested by the Farnsworth–Munsell test). Nevertheless, the patient's chromatic contrast sensitivity was normal, and he retained the ability to use large chromatic contrasts to separate figure from background (as tested by the preattentive vision tasks and the Ishihara pseudoisochromatic plates). We analyze this set of findings in three stages: (i) regions of the nervous system which we believe are normal and unrelated to the observed deficits; (ii) regions of the nervous system which may have contributed to the observed deficits; and (iii) the basis for the dissociation between the preserved and the lost aspects of color processing.

Not a precortical abnormality

Although the patient's history of diabetes and treatment with digoxin raise the possibility of

ocular and retinal abnormalities, it is highly unlikely that these played a role in the patient's color vision deficit. A thorough ophthalmologic exam revealed no ocular pathology. The patient's total error score of 850 on the Farnsworth–Munsell test was far in excess of the performance of diabetics without overt retinopathy on this test (Maione *et al.*, 1984). Distortions of color vision induced by digitalis are well-known, but this is only seen with toxic levels of the drug, and associated with ERG abnormalities (Denden, 1962; Weleber and Shults, 1981). In this patient, digoxin blood levels were low-therapeutic, and normal rod and cone function was demonstrated by flash and flicker electroretinography.

Inherited deficiency of the short wavelength cone, though exceedingly rare, may produce disturbances in color vision not identified by the Ishihara test. However, the diffuse abnormalities on the FM-100 test, with lack of significant axis, are inconsistent with this explanation. Finally, the patient's normal acuity, normal luminance grating contrast sensitivity, and normal chromatic grating contrast sensitivity, rule against retinal explanations of his deficits.

Abnormalities that may have contributed to the observed deficits

In addition to the abnormalities of color vision, this patient manifested associated deficits of disturbed spatial orientation, transient prosopagnosia (difficulty recognizing faces), mild alexia without agraphia, and mild object agnosia. These are typical of the cluster of neuropsychologic abnormalities associated with central disturbances of color vision (Meadows, 1974; Damasio *et al.*, 1980). The rarity of an isolated disturbance of color vision is easily understood. Since normal vision in one hemifield may well mask the presence of dyschromatopsia in the other hemifield, most patients with evident dyschromatopsia have bilateral occipital lesions (one exception is Case 1 of Damasio *et al.*, 1980). Furthermore, vascular and other structural lesions affecting extrastriate visual areas are likely to damage nearby temporal or parietal areas, as well as the underlying white matter.

An MRI image in the present case demonstrated bilateral abnormalities. On the left (corresponding to the hemianopic field), there was an extensive infarction. On the right (corresponding to the dyschromatopic field), there was a smaller infarct which spared the occipital

pole and involved primarily the ventromedial portion of the occipital lobe. There was possible extension of the infarct into the splenium of the corpus callosum.

The ventromedial location of the right-sided infarction, clearly delineated by the MRI study, is consistent with the location of the parenchymal lesion associated with achromatopsia by Damasio *et al.* (1980). Certainly, the other MRI abnormalities are likely the basis of the mild prosopagnosia, object agnosia, and alexia without agraphia (Geschwind, 1965; Benson *et al.*, 1974; Damasio and Damasio, 1983). Here, we focus on the extent to which these lesions may have contributed to the abnormalities associated with color.

The extensive left posterior cerebral infarction, particularly in conjunction with a lesion of the splenium of the corpus callosum, is associated with color naming disturbances in the right visual field (Damasio and Damasio, 1983; DeRenzi *et al.*, 1987), but not typically in a preserved left visual field (Damasio and Damasio 1983). Since subtle abnormalities in color processing appear not to have been examined in such patients, we studied another such patient (W. L., Reuter-Lorenz and Gazzaniga, in preparation) with the methods described above. This patient had a dense right homonymous hemianopsia and alexia without agraphia due to an extensive left occipital lesion, and no involvement of the corpus callosum by MRI. Ishihara testing was normal (10/10 correct), preattentive tests as described above were normal, and performance on the Farnsworth-Munsell test was above-average in the left visual field.

In the present patient, as in the patient of Meadows (1974), a color anomia was ruled out by the patient's retained ability to give color names to familiar objects presented in black-and-white line drawings, and to respond correctly to questions about the colors of common objects. Nevertheless, it is possible that the difficulty in naming color samples devoid of additional cues was due to a disconnection (Geschwind and Fusillo, 1965).

Although a disconnection syndrome may well have interfered with color naming, it is hard to imagine how a disconnection syndrome (or other nonspecific cognitive deficit) would have interfered with FM-100 performance on samples that were close to each other and *not* on samples that were far from each other (Table 1). Furthermore, the excellent performance on contrast-sensitivity indicates that the patient did

not have a general deficit in making near-threshold psychophysical judgements.

Finally, even a normal MRI image cannot exclude selective loss or dysfunction of subpopulations of neurons in area 17, such as those contained in cytochrome-oxidase rich regions (Livingstone and Hubel, 1984). This has been postulated as the basis of high-altitude dyschromatopsia (Green and Lessell, 1977); there appears to be no evidence on its relevance to large-vessel infarction.

A dissociation between different kinds of color processing

While we think that much of the observed color deficits were due to the parenchymal ventromedial extrastriate lesion (both on the basis of our patient and previously-reported patients; Damasio *et al.*, 1980), this is not essential to the main point: a dissociation between different kinds of color processing.

In this patient, chromatic grating sensitivity, which tested the ability to make fine discriminations between regions of equal luminance, was normal. Figure and background could readily be separated on the basis of chromatic contrast (Ishihara testing). The tests of preattentive vision showed that large differences in color were processed as rapidly as large differences in orientation. These tasks, in which performance was nearly normal, rely solely on the ability to process color *differences*. However, saturated samples of specific colors could not be named reliably, color samples could not be placed in sequence, and relative similarities between three color samples could not be judged reliably. These tasks, in which performance was selectively disturbed, all require additional processing beyond mere sensitivity to color differences.

Basis for selective preservation of some forms of color processing

The patient's difficulties with color processing cannot simply be explained as a threshold effect (i.e. that he merely had reduced discrimination for color, and once that threshold was exceeded, his color processing was relatively normal). The task in which a unique rectangle had to be identified on the basis of "orientation \times color" differences proved to be exceedingly difficult for this patient, even though the task made use of gross color differences that he was able to appreciate readily.

An alternative explanation for the patient's behavior, which is more attractive on neurophysiologic grounds, rests on the organization of central visual processing.

The main point is that detection of chromatic differences, and use of chromatic differences to delineate contours, is a simpler task than classification and identification of colors (as tested by color naming tasks) and sequencing colors (as tested by the Farnsworth-Munsell test). In particular, to detect a chromatic difference, it suffices to appreciate an imbalance, or nonzero response, in any color-opponent mechanism; the sign of the chromatic response is irrelevant. However, identification of colors (i.e. assignment of a sample to a unique region of color space) requires appreciation of the sign of the chromatic response and also the synthesis of the outputs of two color-opponent mechanisms. Naming of colors (of unfamiliar objects) is yet a separate process: it requires not only the coding of a region of color space, but also the association of this region with a language term.

A region of color space might be coded by a neuron which is activated when signals of two color-opponent mechanisms are simultaneously within a particular range. Unambiguous signaling of a region of color space cannot be accomplished by a neuron which is sensitive only to the (unsigned) magnitude of two color-opponent mechanisms, or to the sign and magnitude of just one color-opponent mechanism. Similarly, mere appreciation of imbalance of opponent mechanisms does not suffice to determine relative positions of samples in color space, as is required by the Farnsworth-Munsell test.

Previous authors (Green and Lessell, 1977; Pearlman *et al.*, 1978; Damasio *et al.*, 1980; Heywood *et al.*, 1987), have stressed that damage to areas analogous to area V4 of the primate is likely to produce achromatopsia. This inference rests on the studies of Zeki (1973, 1977), which demonstrated a concentration of color-sensitive neurons in this region in monkeys. There is no direct evidence that the ventromedial occipital area involved in the present case corresponds to primate V4, but this area is precisely the extrastriate area involved in the cases listed above.

Although Zeki's studies demonstrate a specialization of V4 for color processing, single neurons that are sensitive to chromatic information are present in the primate striate cortex

with considerable frequency. The spectral bandwidths of these neurons are comparable to those of neurons in V4 (Dow and Gouras, 1973; DeMonasterio and Schein, 1982). These striate cortex neurons pass on color-opponency which is already present at the retinal level (Gouras, 1972). Since the early stages of contour processing occur at these levels, it is likely that this chromatic information is available to delineate contours. Furthermore, although color-sensitivity is a prominent feature of V4 neurons, this cortical area contains cells that are sensitive to other stimulus attributes (such as orientation) in a behaviorally-relevant fashion (Desimone and Schein, 1987; Maunsell and Sclar, 1988).

Zeki (1983) made a distinction between wavelength-sensitive (WL/WLO) and color-coded (CO) cells. Cells sensitive to perceived color (CO) were found only in V4, while cells sensitive to wavelength composition (WL/WLO) were found in both V1 and V4. The present distinction between color difference and color identity is *not* the same as the distinction made by Zeki (1983). Processing at the CO level may well depend on processing at the WL/WLO level (as hypothesized by Zeki), but *both* of these processes (WL/WLO and CO) require more information than detection of chromatic differences.

Comparison with previous cases

There is considerable variation in the degree to which previously-reported patients with central disturbances in color vision have retained the ability to use color differences to separate figure from background. This ability is most often tested with pseudoisochromatic plates (such as the Ishihara plates). Some patients (the present patient, and the patient of Meadows, 1974) identify all or nearly all of the plates correctly. Others (some of Green and Lessell, 1977); the patients of Albert *et al.*, 1975; and Heywood *et al.*, 1987) cannot identify any of the plates. Still others, such as the second patient of Damasio *et al.* (1980), have scattered deficits on Ishihara testing.

Conversely, most patients with a profound loss of color sense (i.e. to whom the world appeared only in whites, blacks, and grays) had lesions that probably involved primary visual cortex as well. Critchley (1965) comments that all patients with profound achromatopsia have an associated field defect on the side of the achromatopsia; the single exception appears to

be the patient subsequently reported by Albert *et al.* (1975). Both of Damasio *et al.*'s (1980) patients reported that the world appeared only in whites, blacks, and grays. Although one of their CT studies did not demonstrate infarction of area 17, the physiological evidence presented in that report suggests a functional derangement of striate cortex in both cases. (i) Both patients had markedly abnormal VEP's elicited by chromatic stimulation; animal studies indicate that the main origin for this response is primary visual cortex (Previc, 1986). (ii) Both patients had partial field cuts (to achromatic stimuli as well) homolateral to the achromatopsia.

In summary, previously-studied patients had evidence of a range of residual color-discrimination abilities, as manifest by Ishihara testing and their subjective reports. The patients with the most profound loss of color sense had associated findings suggestive of major co-existing lesions of primary visual cortex as well, such as visual field cuts within the dyschromatopic field and abnormal evoked potentials.

In contrast, the case reported here has strong evidence for more nearly normal function of the striate cortex: preserved evoked-potentials under isoluminant conditions (at a single derivation), preserved luminance and chromatic contrast-sensitivity, preserved visual acuity, no achromatic visual field loss in the dyschromatopic field, and sparing by MRI.

Chromatic processing begins in the retina, with opponent mechanisms clearly expressed at the ganglion cell level (Gouras, 1972). Opponent chromatic information is well-preserved in the geniculocalcarine pathway (DeMonasterio and Schein, 1982). The best evidence so far indicates that the subcortical pathway from retina to superior colliculus and pulvinar does not contribute to color vision, because the retinotectal ganglion cells are not color-opponent (Schiller and Malpeli, 1977). The major cortical projection of color-opponent lateral geniculate neurons is area 17 (Covey, 1964; Wilson and Cragg, 1967); there is evidence for a minor direct projection from the lateral geniculate to V4 (Yukie and Iwai, 1981) whose physiology is as yet undefined. Thus, although the precise locus of neurons responsible for detection tasks is not known, the patient's normal psychophysical detection thresholds imply that his chromatic processing is preserved at least as far as striate cortex. Preservation of the VEP for isoluminant stimuli also implies preservation of

color-sensitive units in striate cortex (Previc, 1986).

Color identification, color classification, and determination of the relative distances of samples in color space are all more complex processes than color discrimination. These processes require substantial cortical processing, while color discrimination relies on information which is simply-extracted from the geniculate input. A variety of occipital lesions may contribute to abnormalities of these later stages of color processing. However, if striate cortex is preserved, normal sensitivity to color differences should be expected from the preservation of opponent mechanisms present in the striate cortex. Conversely, in the analysis of acquired abnormalities of color vision, loss of color discrimination (or chromatic contrast sensitivity) should suggest damage to striate cortex.

Acknowledgements—We thank Dr Scott E. Brodie for performing the electroretinography. This work was supported in part by grants EY1472, EY6871, NS877, and NS03346 from the NIH, and additional support from the Hartford Foundation, the MacArthur Foundation, the McKnight Foundation, and the Sloan Foundation.

REFERENCES

- Albert M. L., Reches A. and Silverberg R. (1975) Hemianopic color blindness. *J. Neurol. Neurosurg. Psychol.* **38**, 546–549.
- Benson D. F., Segarra J. and Albert M. L. (1974) Visual agnosia-prosopagnosia: a clinico-pathologic correlation. *Arch. Neurol.* **30**, 307.
- Covey A. (1964) Projection of the retina on to striate and peristriate cortex in the squirrel monkey, *Saimiri sciurus*. *J. Neurophysiol.* **27**, 366–396.
- Critchley M. (1965) Acquired anomalies of colour perception of central origin. *Brain* **88**, 711–724.
- Damasio A. and Damasio H. (1983) The anatomic basis of pure alexia. *Neurology* **33**, 1573–1583.
- Damasio H. and Damasio A. (1979) "Paradoxical" ear extinction in dichotic listening: possible anatomic significance. *Neurology* **29**, 644–653.
- Damasio A., Yamada Y., Damasio H., Corbett J. and McKee J. (1980) Central achromatopsia: behavioral, anatomic, and physiological aspects. *Neurology* **30**, 1064–1071.
- DeMonasterio F. M. and Schein S. J. (1982) Spectral bandwidths of color-opponent cells of geniculocortical pathway of macaque monkeys. *J. Neurophysiol.* **47**, 214–224.
- Denden A. (1962) Elektroretinographische Spektralsensitivität bei Farbigesehe nach Acetyldigitoxinbehandlung. *Albrecht Von Graefes Arch. Klin. exp. Ophthalm.* **165**, 185–194.
- DeRenzi E., Zambolin A. and Crisi G. (1987) The pattern of neuropsychological impairment associated with left posterior cerebral artery infarcts. *Brain* **110**, 1099–1116.
- Desimone R. and Schein S. J. (1987) Visual properties of

- neurons in area V4 of the macaque: sensitivity to stimulus form. *J. Neurophysiol.* **57**, 835–868.
- Dow B. M. and Gouras P. (1973) Color and spatial specificity of single units in Rhesus monkey foveal striate cortex. *J. Neurophysiol.* **36**, 79–100.
- Farnsworth D. (1957) *The Farnsworth–Munsell 100-Hue Test for the Examination of Color Discrimination*. Munsell Color Company, Baltimore, MD.
- Geschwind N. (1965) Disconnexion syndromes in animals and man. *Brain* **88**, 237–294, 585–644.
- Geschwind N. and Fusillo M. (1965) Color-naming defects in association with alexia. *Arch. Neurol.* **15**, 137–146.
- Gouras P. (1972) Color opponency from fovea to striate cortex. *Invest. Ophthalmol.* **11**, 427–434.
- Green G. J. and Lessell S. (1977) Acquired cerebral dyschromatopsia. *Arch. Ophthalmol.* **95**, 121–128.
- Heinemann E. G. (1972) Simultaneous brightness induction. In *Handbook of Sensory Physiology*, edited by Jameson D. and Hurvich L., Vol. VII/4. Springer, Berlin.
- Helson H. (1963) Studies of anomalous contrast and assimilation. *J. Opt. Soc. Am.* **53**, 179–184.
- Heywood C. A., Wilson B. and Cowey A. (1987) A case study of cortical colour “blindness” with relatively intact achromatic distinction. *J. Neurol. Neurosurg. Psychol.* **50**, 22–29.
- Holmes G. (1918) Disturbance of vision by cerebral lesions. *Br. J. Ophthalmol.* **2**, 353–384.
- Julesz B. (1971) *Foundations of Cyclopean Perception*. University of Chicago Press, Chicago.
- Kaplan E., Goodglass H., Weintraub S. and Segal O. (1983) *Boston Naming Test*. Lea & Febiger, Philadelphia.
- Livingstone M. S. and Hubel D. H. (1984) Anatomy and physiology of a color system in the primary visual cortex. *J. Neurosci.* **4**, 309–356.
- Maione M., Strata A., Scoccianti L., Bontempelli G., Berardi D., Carnevali R., Tardini M. G. and Caronna S. (1984) The performance at the FM100-Hue test as a risk factor for diabetic retinopathy. In *Color Vision Deficiencies VII*, edited by Verriest G., pp. 387–392. Junk Publishers, The Hague.
- Maunsell J. H. R. and Sclar G. (1988) Neurons in area V4 of the macaque monkey signal task-specific information. *Invest. Ophthalmol. visual Sci.* **29**, 22.
- Meadows J. C. (1974) Disturbed perception of colours associated with localized cerebral lesions. *Brain* **97**, 615–632.
- Milkman N., Schick G., Rossetto M., Ratliff F., Shapley R. and Victor J. D. (1980) A two-dimensional computer-controlled visual stimulator. *Behav. Res. Meth. Instrum.* **12**, 283–292.
- Mullen K. T. (1985) The contrast sensitivity of human color vision to red-green and blue-yellow chromatic gratings. *J. Physiol., Lond.* **359**, 381–400.
- Pearlman A. L., Birch J. and Meadows J. C. (1978) Cerebral color blindness: an acquired defect in hue discrimination. *Ann. Neurol.* **5**, 253–261.
- Pessin M. S., Lathi E. S., Cohen M. B., Kwan E. S., Hedges T. R. III and Caplan L. R. (1987) Clinical features and mechanism of occipital infarction. *Ann. Neurol.* **21**, 290–299.
- Previc F. H. (1986) Visual evoked potentials to luminance and chromatic contrast in rhesus monkeys. *Vision Res.* **26**, 1897–1907.
- Schiller P. H. and Malpeli J. G. (1977) Properties and tectal projections of monkey retinal ganglion cells. *J. Neurophysiol.* **40**, 428–445.
- Schnapf J. C., Kraft T. W. and Baylor D. A. (1987) Spectral sensitivity of human cone photoreceptors. *Nature, Lond.* **325**, 439–441.
- Shapley R. (1986) The importance of contrast for the activity of single neurons, the VEP, and perception. *Vision Res.* **26**, 45–61.
- Shapley R. and Reid R. C. (1985) Contrast and assimilation in the perception of brightness. *Proc. Natl. Acad. Sci. U.S.A.* **82**, 5983–5986.
- Sidtis J. J., Volpe B. T., Holtzman J. D., Wilson D. H. and Gazzaniga M. S. (1981a) Cognitive interaction after staged callosal section: evidence for transfer of semantic information. *Science, N.Y.* **212**, 344–346.
- Sidtis J. J., Volpe B. T., Wilson D. H., Rayport M. and Gazzaniga M. S. (1981b) Variability in right hemisphere language function after callosal section: evidence for a continuum of generative capacity. *J. Neurosci.* **1**, 323–331.
- Smith V. C. and Pokorny J. (1975) Spectral sensitivity of the foveal cone photopigments between 400 and 500 nm. *Vision Res.* **15**, 161–171.
- Springer S. P. and Gazzaniga M. S. (1975) Dichotic testing of partial and complete split brain subjects. *Neuropsychologia* **13**, 341–346.
- Treisman A. (1982) Perceptual grouping and attention in visual search for features and for objects. *J. exp. Psychol. Human Percept. Perform.* **8**, 194–214.
- Victor J. D. (1988) Evaluation of poor performance and asymmetry in the Farnsworth–Munsell 100-hue test. *Invest. Ophthalmol. visual Sci.* **29**, 476–481.
- Wechsler D. (1945) A standardized memory scale for clinical use. *J. Psychol.* **19**, 87–95.
- Weleber R. G. and Shults W. T. (1981) Digoxin retinal toxicity: clinical and electrophysiologic evaluation of a cone dysfunction syndrome. *Arch. Ophthalmol.* **99**, 1568–1572.
- Wilson M. E. and Cragg B. G. (1967) Projections from the lateral geniculate nucleus in the cat and monkey. *J. Anat.* **101**, 677–692.
- Yukie M. and Iwai E. (1981) Direct projection from the dorsal lateral geniculate nucleus to the prestriate cortex in macaque monkeys. *J. comp. Neurol.* **201**, 81–97.
- Zeki S. M. (1973) Colour coding in rhesus monkey prestriate cortex. *Brain Res.* **53**, 422–427.
- Zeki S. M. (1977) Colour coding in the superior temporal sulcus of rhesus monkey visual cortex. *Proc. R. Soc. Lond. B* **197**, 195–223.
- Zeki S. M. (1983) Colour coding in the cerebral cortex: the reaction of cells in monkey visual cortex to wavelengths and colours. *Neuroscience* **9**, 741–765.