



Cortical mapping in brain tumor resection: Stimulation parameters and seizures

Sonia K. Sandhu, DO, Erik J. Kobylarz, MD PhD, Syed A. Hosain, MD

Department of Neurology and Neuroscience, Weill Cornell Medical College, New York, NY

Introduction

During surgery, cortical mapping and stimulation is associated with the risk of intraoperative electrographic and clinical seizures.

Objectives

To determine the relationship between effective stimulation intensities and the incidence of intraoperative electrographic and clinical seizures.

Methods

Intraoperatively, patients underwent cortical stimulation after identification of sensorimotor cortex by SSEP recording of phase reversals. Stimulation at increasing intensities (in 2 mA (peak-to-peak) steps) was performed using an Ojemann cortical stimulator (1 second trains of 1 msec biphasic pulses at 60 Hertz). The electrocorticogram was simultaneously recorded with an 8-element strip subdural electrode at nearby sites. The presence or absence of motor, sensory, and/or speech responses, afterdischarges, clinical, and electrographic seizures were documented.

Results

From January 2001 to December 2002, 116 patients were studied. Intraoperative SSEPs were performed in 91% of patients and tentatively identified sensorimotor cortex by phase reversal in 89 % of patients. Stimulation intensities required to elicit responses ranged from 2.0 milliamperes (mA) to 20 mA (peak-to-peak) with a mean of 7.2 mA (SD 3.45). Eighteen percent of patients had clinical seizures, 22% of patients had electrographic seizures, and 9% had both. The presence of seizures did not correlate with stimulation intensity (p-value 0.25).

Conclusions

Intraoperative clinical and electrographic seizures are not uncommon during cortical stimulation and mapping. In this cohort, most patients required less than 10 mA to identify eloquent cortex. There was no correlation between stimulation intensities and intraoperative risk of seizures.

References

- Bezard E, et al. Cortical stimulation and epileptic seizure: A study of the potential risk in primates. *Neurosurgery* 1999, 45:346-350.
- Luciano D, et al. Electrocorticography during cortical stimulation. *Adv Neurol* 1993;63:87-102.

Figure 1

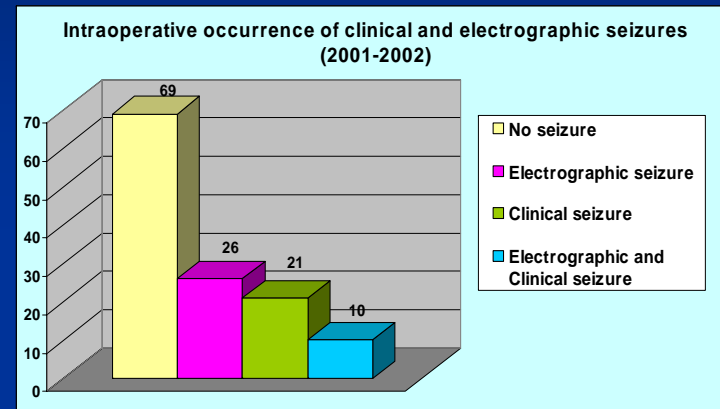


Figure 2

